



Système de compression dynamique FMF FMF Dynamic Compressor System

Indication

Traitement non invasive du pectus carinatum
Non-invasive treatment of pectus carinatum



Bibliographie / Bibliography

Dynamic compression system for the correction of pectus carinatum

Martinez-Ferro M¹, Fraire C, Bernard S.

¹Department of Pediatric Surgery, Fundacion Hospitalaria's Private Children's Hospital, Buenos Aires, Argentina.
martinezferro@fibertel.com.ar martinezferro@fibertel.com.ar

Semin Pediatr Surg. 2008 Aug;17(3):194-200. doi: 10.1053/j.sempedsurg.2008.03.008.

Abstract

Between April 2001 and 2007, we treated 208 patients with pectus carinatum by using a specially designed dynamic compression system (DCS) that uses a custom-made aluminum brace. Recently, an electronic pressure measuring device was added to the brace. Results were evaluated by using a double-blinded subjective scale (1 to 10). A total of 208 patients were treated over 6 years; 154 were males (74%) and the mean age was 12.5 years (range 3 to 18 years). Mean utilization time was 7.2 hours daily for 7 months (range 3 to 20 months). A total of 28 (13.4%) patients abandoned treatment and were not evaluated for final results. Of the 180 remaining patients, 112 completed treatment. A total of 99 of 112 (88.4%) had good to excellent results scoring between 7 and 10 points, and 13 (11.6%) patients scored 1 to 6 points and were judged as poor or failed results. The "Pressure for Initial Correction" (PIC) in pounds per square inch (PSI) proved that starting treatment with less than 2.5 PSI avoids skin lesions. Patients who require pressures higher than 7.5 PSI should not be treated with this method. We found a good correlation between PIC versus treatment duration and outcome. DCS is an effective treatment for pectus carinatum with minimal morbidity. We suggest that patients with pectus carinatum have a trial of compression therapy before recommending surgical resection. The use of pressure measurement avoids complications such as skin lesions, partial or poor results, and patient noncompliance.

PMID: 18582825 [PubMed - indexed for MEDLINE]

International innovations in pediatric minimally invasive surgery: the Argentine experience

Martinez-Ferro M.

Division Department of Surgery, Fundación Hospitalaria Private Children's Hospital, Ciudad Autónoma de Buenos Aires, Argentina.
martinezferro@fibertel.com.ar

J Pediatr Surg. 2012 May;47(5):825-35. doi: 10.1016/j.jpedsurg.2012.01.030.

Abstract

This is a presentation about innovations in pediatric minimally invasive surgery and a review of the Argentine experience. The most representative are (1) the thoracoscopic treatment of long gap esophageal atresia with novel techniques; (2) the nonsurgical and minimally invasive treatment of chest wall deformities, particularly of pectus carinatum; and (3) the use of magnetic surgical devices in classic laparoscopy and transumbilical surgery.

Copyright © 2012 Elsevier Inc. All rights reserved. PMID: 22595556 [PubMed - indexed for MEDLINE]

[Dynamic compression brace for pectus carinatum]

[Article in Dutch]

de Beer SA¹, de Jong JR, Heij HA.

¹Kinderchirurgisch Centrum Amsterdam, Emma Kinderziekenhuis, AMC en VUmc, Amsterdam.

Ned Tijdschr Geneeskd. 2013;157(46):A6796.

Abstract

Pectus carinatum occurs in one of 1500-1700 people and may lead to physical, cosmetic and psychosocial problems. Surgical treatment of pectus carinatum is performed using the 'Ravitch procedure'. An alternative and less invasive treatment consists of external compression with a brace. Results are often disappointing because of skin complications, a low level of comfort of the brace and low compliance. Nowadays a new brace (dynamic compression brace) exists with which the comfort and thus the compliance can be increased by measuring and regulating the pressure of correction during the treatment. This leads to better results and fewer complications. In 80-90% of patients the results are good to excellent and an operation can be avoided. This new brace is therefore a less invasive, cheap and safe alternative to the Ravitch procedure in the treatment of pectus carinatum in children.

PMID: 24220182 [PubMed - in process]

MEDICALEX

20 avenue Aristide Briand 92220 BAGNEUX – France www.medicallex.info
Tél : +33 (0)1 46 11 16 20 Fax : +33 (0)1 46 65 41 41 francemed@wanadoo.fr

Staged management of pectus carinatum

Cohee AS¹, Lin JR, Frantz FW, Kelly RE Jr.

¹Children's Hospital of The King's Daughters, Norfolk, VA 23507, USA.

J Pediatr Surg. 2013 Feb;48(2):315-20. doi: 10.1016/j.jpedsurg.2012.11.008.

Abstract

AIM: The aim was to report the treatment of *pectus carinatum* with a novel Argentine *brace* and operation.

METHODS: The bracing and clinical data of 137 consenting *pectus carinatum* patients treated between October 2008 and December 2011 were reviewed for outcome. Institutional approval was obtained. Data are reported as median (range).

RESULTS: Median age 122 bracing patients was 14 (10-28) years with 67 (55%) progressing under active treatment. Five patients (4%) were lost to follow-up, and thirteen (11%) failed treatment. Thirty-seven patients (30%) exhibited flattening of the sternum after 6 (1-24) months without surgery. After flattening, patients then wore the *brace* for progressively fewer hours each day as a "retainer" for 5 (3-19) months. Five patients (4%) experienced recurrence 5 (3-7) months after *brace* treatment was discontinued. Complications were limited to transient skin breakdown in nine patients. Three of the 13 Argentine *brace* failures and 15 other *pectus carinatum* patients were treated surgically. Thirteen underwent Abramson's minimally invasive operation and five an open repair, all with good initial correction. For Abramson repairs, seven patients have had bars removed, with results rated as excellent (n=4), good (n=2), and failure (n=1, converted to open with excellent result later). In three patients with stiff chests, costal cartilage was resected thoracoscopically during the Abramson repair with measurably improving compliance.

CONCLUSION: Staged treatment of *pectus carinatum* allows most teenagers to be managed non-operatively. For patients who fail bracing or are not amenable to bracing, minimally invasive surgical treatment for *pectus carinatum* is a viable option.

Copyright © 2013 Elsevier Inc. All rights reserved. PMID: 23414858 [PubMed - indexed for MEDLINE]

Preliminary study of efficacy of dynamic compression system in the correction of typical pectus carinatum

Lopez M¹, Patoir A, Varlet F, Perez-Etchepare E, Tiffet T, Villard A, Tiffet O.

¹Unit of Chest Wall Deformities Children and Adults, University Hospital of Saint Etienne, Saint Etienne, France.

Eur J Cardiothorac Surg. 2013 Nov;44(5):e316-9. doi: 10.1093/ejcts/ezt425. Epub 2013 Sep 6.

Abstract

OBJECTIVES: This preliminary study evaluates, by qualitative score, the efficacy of the dynamic compression system (DCS) with a pressure-measuring device in the treatment of pectus carinatum (PC) as an alternative to surgery.

METHODS: A total of 68 patients (infants, adolescents and young adults) presenting with typical PC (64 males and 4 females) were evaluated in our Chest Wall Deformities Unit, between October 2011 and February 2013. The criteria for including subjects were: patients with typical condrogladiolar PC and pressure for initial correction (PIC) \leq 9 PSI (pound square inch). Seven patients were excluded in this study: three typical PC were treated by minimal invasive surgery (Abramson technique) due to highly elevated PIC and four atypical PC, hybrids forms (PE and PC) were treated by cup suction for pectus excavatum and by the DCS for the PC. The management protocol included: adjustment of the DCS, strengthening exercises and monthly clinical follow-up. The partial and final results were evaluated by the patients, by their parents or by both, using a qualitative scoring scale that was measured in a three-step grading system, where C is a low or very low result, B is acceptable and A is a very good or excellent result.

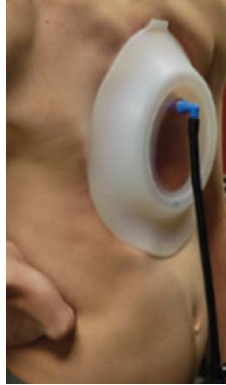RESULTS: A total of 61 patients (59 males and 2 females) presenting with typical PC were treated by the DCS and included: symmetric PC in 43 cases and asymmetric PC in 18 cases. The mean age was 13.5 years (5-25). The mean PIC was 6.3 PSI (3-9 PSI). The mean utilization time was 19 h daily. The patients were divided into three groups. In Group I, consisting of 35 cases, all the patients have already completed the treatment with excellent aesthetic results (A). In 12 cases, Group II, the normal shape of the thorax has been obtained; all the patients in this group rated their results as excellent (A); however, these patients are still wearing the brace as a retainer for 3 additional months. Fourteen patients, Group III, are progressing and improving under active treatment, and surgeons and patients are very satisfied with the initial results. None of the 61 patients in this study abandoned the treatment and no complications were found.

CONCLUSIONS: This preliminary study demonstrated that the DCS with a pressure-measuring device is a minimal invasive system effective for treatment of PC in patients where the anterior chest wall is still compliant. The control of different pressure measurements could be used as the inclusion criterion as well as a predictive factor for aesthetic results and treatment duration.

PMID: 24014551 [PubMed - in process]

Indication

Traitement non invasif du pectus excavatum
Non-invasive treatment of pectus excavatum



Bibliographie / Bibliography

The vacuum bell for conservative treatment of pectus excavatum: the Basle experience

Haecker FM.

Department of Pediatric Surgery, University Children's Hospital, Spitalstrasse 33, 4056, Basel, Switzerland. frankmartin.haecker@ukbb.ch

Pediatr Surg Int. 2011 Jun;27(6):623-7. doi: 10.1007/s00383-010-2843-7.

Abstract

OBJECTIVE: Surgical repair of pectus excavatum (PE) in childhood is a well-established procedure. Previously used operative techniques to correct PE were largely based on the Ravitch technique. Since about 10 years, the minimally invasive repair (MIRPE) by Nuss is well established. Conservative treatment with the vacuum bell to elevate the funnel in patients with PE represents a potential alternative to surgery in selected patients.

METHODS: A suction cup is used to create a vacuum at the anterior chest wall. Three different sizes of vacuum bell exist which are selected according to the individual patients age. When creating the vacuum, the lift of the sternum is obvious and remains for a different time period. The device should be used for a minimum of 30 min (twice/day), and may be used up to a maximum of several hours daily.

RESULTS: One hundred and thirty-three patients (110 males, 23 females) aged from 3 to 61 years (median 16.21 years) used the vacuum bell for 1 to a maximum of 36 months. Computed tomographic scans showed that the device lifted the sternum and ribs immediately. In addition, this was confirmed thoracoscopically during the MIRPE procedure. One hundred and five patients showed a permanent lift of the sternum for more than 1 cm after 3 months of daily application. Thirteen patients stopped the application and underwent MIRPE. Relevant side effects were not noted.

CONCLUSION: The vacuum bell has proved to be an alternative therapeutic option in selected patients suffering from PE. The initial results proved to be dramatic, but long-term results are so far lacking, and further evaluation and follow-up studies are necessary.

PMID: 21240610 [PubMed - indexed for MEDLINE]

Intraoperative use of the vacuum bell for elevating the sternum during the Nuss procedure

Haecker FM¹, Sesia SB.

¹Division of Pediatric Surgery, University Children's Hospital Basel, University of Basel, Basel, Switzerland. frankmartin.haecker@ukbb.ch

J Laparoendosc Adv Surg Tech A. 2012 Nov;22(9):934-6. doi: 10.1089/lap.2012.0030.

Abstract

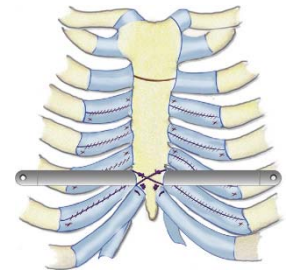
OBJECTIVE: To evaluate the routine use of the vacuum bell for elevating the sternum during minimally invasive repair of pectus excavatum (MIRPE) (the Nuss procedure).

SUBJECTS AND METHODS: This was a retrospective evaluation of a prospective database including all patients who underwent MIRPE at our institution between 2005 and 2010. Data included the patient's demographic characteristics, age at surgery, gender, Haller index, duration of surgery, and intraoperative complications.

RESULTS: Fifty patients from 9 to 28 years old (average, 14.95 years) were observed, including 39 males and 11 females. The preoperative Haller index was between 3.25 and 7.4 (average, 5.05). Mean duration of surgery was 58 minutes (range, 45-92 minutes). The use of the vacuum bell led to a clear elevation of the sternum as confirmed by thoracoscopy. Advancement of the pectus introducer and placement of the pectus bar were safe, successful, and uneventful in all patients. No cardiac and/or pericardial lesion was noted as well as no lesion of the mammary vessels.

CONCLUSIONS: The intraoperative use of the vacuum bell during the MIRPE is safe and effective as it facilitates the retrosternal dissection and the insertion of the pectus bar. If available, we recommend the routine use of this device for MIRPE.

PMID: 23137116 [PubMed - indexed for MEDLINE]



Indication

Traitement chirurgical du pectus excavatum par
technique de Baronofsky modifiée
*Surgical treatment of pectus excavatum by
modified Baronofsky's technique*

Bibliographie / Bibliography

Simplified open repair for anterior chest wall deformities. Analysis of results in 205 patients.

Wurtz A¹, Rousse N, Benhamed L, Conti M, Hysi I, Pinçon C, Nevière R.

¹Thoracic and Cardiac Surgery Division, Albert Calmette Hospital, Lille University Teaching Hospital, 59037 Lille cedex, France. alain.wurtz@chru-lille.fr

Orthop Traumatol Surg Res. 2012 May;98(3):319-26. doi: 10.1016/j.otsr.2011.11.005. Epub 2012 Apr 6.

Abstract

INTRODUCTION: Pectus deformities are the most frequently seen congenital thoracic wall anomalies. The cause of these conditions is thought to be abnormal elongation of the rib cartilages. We here report our clinical experience and the results of a sternochondroplasty procedure based on the subperichondrial resection of the elongated cartilages.

HYPOTHESIS: This technique is a valuable surgical strategy to treat the wide variety of pectus deformities.

PATIENTS AND METHODS: During the period from October 2001 through September 2009, 205 adult patients (171 men and 34 women) underwent pectus excavatum (181), carinatum (19) or arcuatum (5) repair. The patients' pre and postoperative data were collected using a computerized database, and the results were assessed with a minimum 2-year follow-up.

RESULTS: The postoperative morbidity rate was minimal and the mortality was nil. The surgeon graded cosmetic results as excellent (72.5%), good (25%) or fair (2.5%), while patients reported better results. Patients with pectus excavatum were found to have much more patent foramen ovale (PFO) than the normal adult population, which occluded after the procedure in 61% of patients, and significant improvement was found in exercise cardiopulmonary function and exercise tolerance at the 1-year follow-up.

DISCUSSION: Our sternochondroplasty technique based on the subperichondrial resection of the elongated cartilages allows satisfactory repair of both pectus excavatum and sternal prominence. It is a safe procedure that might improve the effectiveness of surgical therapy in patients with pectus deformities.

Copyright © 2012 Elsevier Masson SAS. All rights reserved. PMID: 22483862 [PubMed - indexed for MEDLINE]

Results of modified Baronofsky surgical repair in anterior chest wall deformities

Conti M¹, Benhamed L, Moura BS, Akkad R, Porte H, Wurtz A

¹Chirurgie Thoracique Hopital Calmette CHU Lille, Lille, France

Interact CardioVasc Thorac Surg 2008;7(Supplement 2):S167. doi: 10.1510/icvts.2008.0000S4

OBJECTIVE: To evaluate the immediate and mean term results of the surgical treatment of pectus deformities using modified Baronoesky repair technique.

METHODS: From May 2001 to December 2007, we operated 122 patients for an anterior chest wall deformities; 102 patients (84%) presented a pectus excavatum (PE), 16 (13%) a Pectus Carinatum (PC) and 4 (3%) a Pectus Arcuatum (PA). Surgical technique includes subperichondrial excision of all deformed costal cartilages, followed by a transverse sternal osteotomy, anteriorly in case of PE and posteriorly in case of PC and PA. As the perichondral sheaths are totally preserved, they are stitched in continuous layers, giving a shortening effect. In case of PE the sternum is then secured anteriorly by a retrosternal metallic strut during about six months. The 7th cartilages, partially resected, are then stitched to the xyphoid. We evaluated length of incision, per-operative blood lost, length of time of surgical procedure, length of hospital stay and patients satisfaction rate.

RESULTS: One hundred and twenty-two patients (103 men, 19 women) with a mean age of 24 years (± 9 years) were included. Mean operative time was 200 min (± 54 min), mean preoperative blood loss was 140 ml (± 80 ml), mean length of incision was 12.9 cm (± 2 cm), mean hospital stay was 3.9 days (± 1.2 days). Minor morbidity was observed in 12 (10%) patients. Follow-up was complete for 120 patients (98.4%); mid-term results (follow-up superior to 2 years) were evaluated in 88 patients (72%). Post operative 3 D CT-scan demonstrated, at six months, calcification of the resected cartilages beds, securing mid-term results of the deformity correction. Cosmetic result is excellent in 73 patients (83%), satisfactory in 15 (17%).

CONCLUSIONS: The procedures described here are safe, yielded excellent mid-term results with low morbidity and no mortality, and produced high patient satisfaction.

Cardiopulmonary response following surgical repair of pectus excavatum in adult patients

Neviere R¹, Montaigne D, Benhamed L, Catto M, Edme JL, Matran R, Wurtz A.

¹Service d'explorations fonctionnelles respiratoires EFR Hôpital Calmette CHU Lille, Lille, France. meviere@univ-lille2.fr

Eur J Cardiothorac Surg. 2011 Aug;40(2):e77-82. doi: 10.1016/j.ejcts.2011.03.045. Epub 2011 May 12.

Abstract

OBJECTIVE: Severe pectus excavatum are common in adult patients, often causing psychological complaints and physiological impairments. Although lung function at rest may minimally deteriorate after surgical correction, it remains unclear if surgery improves exercise capacity. The objective of present study is to assess whether the surgical repair of pectus excavatum in adults would improve exercise tolerance.

METHODS: A prospective study was performed to compare pulmonary and cardiovascular function at rest and at maximal exercise, before, and at 1 year after pectus excavatum repair.

RESULTS: From December 2005 to May 2009, 120 adult patients underwent pectus excavatum repair. Of these patients, 70 (nine women, 61 men) underwent thorough preoperative, 6-, and 12-month postoperative assessments, and were included in the present study. Age ranged from 18 to 62 years (mean 27 years). The pectus index (Haller index) was 4.5 ± 1.1 . Lung function tests at rest were within the normal range, whereas maximal oxygen uptake (peak VO_2) was only $77 \pm 2\%$ of the predicted value. At 1-year follow-up, the pectus excavatum repair was associated with minor changes in lung function tests and significant increase ($p=0.0005$) in VO_2 ($87 \pm 2\%$ of the predicted value). Postoperative O_2 pulse increase at maximal exercise suggested that aerobic capacity improvement was the result of better cardiovascular adaptation at maximal workload.

CONCLUSION: These results demonstrate sustained improvement in exercise cardiopulmonary function at 1-year follow-up of pectus excavatum surgical repair in adult patients.

Copyright © 2011 European Association for Cardio-Thoracic Surgery. Published by Elsevier B.V. All rights reserved PMID: 21570313
[PubMed - indexed for MEDLINE]

Staged repair of pectus excavatum during an aortic valve-sparing operation

Rousse N¹, Juthier F, Prat A, Wurtz A.

¹Pôle de Chirurgie Thoracique, Hôpital Albert Calmette, CHU de Lille, Lille, France.

J Thorac Cardiovasc Surg. 2011 May;141(5):e28-30. doi: 10.1016/j.jtcvs.2011.01.019. Epub 2011 Mar 11.

PMID: 21397272 [PubMed - indexed for MEDLINE]



Plaque pour pectus excavatum du Pr Jouve Pr Jouve pectus excavatum plate

Indication

Traitement mini-invasif du pectus excavatum par technique de Nuss
Nuss minimally invasive repair of pectus excavatum



Bibliographie / Bibliography

Child pectus excavatum: correction by minimally invasive surgery

Felts E¹, Jouve JL, Blondel B, Launay F, Lacroix F, Bollini G.

¹Department of Pediatric Orthopaedic Surgery, Children Timone Hospital, rue Saint-Pierre, boulevard Jean-Moulin, Marseille, cedex 513385 France.

Orthop Traumatol Surg Res. 2009 May;95(3):190-5. doi: 10.1016/j.otsr.2009.03.001. Epub 2009 Apr 18.

Abstract

INTRODUCTION: Pectus excavatum (PE) is a congenital deformity essentially responsible for an unattractive aspect, much more rarely for compression problems. The classical treatments consist either in filling the excavation or in open thoracic reconstruction (the Ravitch technique). Alternatively, the treatment described by Nuss raises the sternum with a retrosternal metallic bar placed under thoracoscopic guidance. We present the preliminary results of a series of 25 children operated on using this technique.

HYPOTHESIS: The minimally invasive procedure described by Nuss is a valid surgical strategy to treat PE.

MATERIALS AND METHODS: Twenty-five patients were operated on between February 2004 and April 2007 by the same surgeon. Nineteen of these patients presented a purely cosmetic indication. The six other patients were considered to have a more severe form of PE, with cardiorespiratory repercussions. In this group, there were two cases of Marfan syndrome and two patients presenting a history of previous cardiothoracic surgery. The technique has always consisted in placing a retrosternal bar through two lateral incisions. The surgery was always performed with right lung exclusion and was guided by thoracoscopy in 21 cases. In four particularly severe cases, a subxiphoid approach was required, making endoscopic guidance unnecessary. The severity of the lesion was evaluated by the Haller Index. All the patients had regular clinical follow-up (at three weeks, three months, and then every six months); assessment of pain, satisfaction with the cosmetic results, and perceived improvement in respiratory function were the criteria used for this follow-up.

RESULTS: The cosmetic result was judged to be positive by 24 patients. One patient was dissatisfied (because of the asymmetrical shape resulting from the use of a single implant). Five patients presented minor complications with no repercussions on the cosmetic or functional result. One case of secondary bar displacement required revision on day 15. Following this revision evolution was uncomplicated (discharge on day 7 and activities resumed at three weeks). Finally, the hardware was removed at a delay after implantation ranging from one to two years. As of today, 13 patients have had their hardware removed with no complications or loss of the initial result.

DISCUSSION: The original indication of the Nuss technique remains symmetrical PE in seven to 14-year-old children. The insubstantial scarring makes the technique valuable in the purely cosmetic forms of the condition. Based on this series, our technique has evolved toward certain adjustments depending on the severity and the etiology of the lesion. The most reported complication in the literature is secondary displacement of the bars. This problem is easily controlled by attaching the bar to a rib. Over the years, we have modified the implant design so as to improve its tolerance and stability. In asymmetrical forms of PE, implanting two bars has provided better efficacy. When a major form is present or when there is a history of cardiorespiratory problems, we recommend a short subxiphoid incision to release the pleural and pericardial adhesences, precluding the need for thoracoscopic guidance. With these simple adjustments, this technique gains in reliability for cosmetic indications and its use can be extended to specific forms such as collagenosis or postoperative deformities.

LEVEL OF EVIDENCE: Level IV. Therapeutic Study.

PMID: 19376762 [PubMed - indexed for MEDLINE]

Minimal invasive repair of pectus excavatum in children and adolescents: Surgical technique

Jouve JL¹

¹Université de la Méditerranée, service d'orthopédie pédiatrique, hôpital Timone enfants, 264, rue Saint-Pierre, 13385 Marseille cedex 5.

Conférences d'enseignement de la SOFCOT 2010;99:385-405. doi: 10.1016/B978-2-8101-0057-6.00019-4

Abstract

The minimal invasive technique as described by Nuss is an interesting option for the surgical management of pectus excavatum. The best indications are symmetrical midline deformities in patients under 20 years of age, owing to the elasticity of the thorax before this age. In adults, correction becomes more difficult due to increased stiffness of the thorax, the procedure is associated with more complications and the outcome becomes more and more uncertain with advancing age. Asymmetric deformities with rotation of the sternum in the transverse plane, which combine pectus excavatum and pectus carinatum deformities, are also debatable indications.

The principle is based on realignment of the sternum with respect to the two hemithoraces using a retrosternal bar which is introduced under thoracoscopic control. The bar rests on the lateral parts of the thorax to achieve a wide distribution of the forces. The main difficulty is to introduce the pectus guide across the mediastinum, between the sternum and the pericardium, and to gently push its extremity through the intercostal space on the opposite side. Two bars may be necessary in cases with a major deformity affecting a large part of the sternum proximally. Several cases of secondary displacement of the bar(s) have been reported in literature. We systematically fix the bar to a rib with two wires and the technique was never associated with bar dislocation in our experience. The main issue is the risk of cardiac injuries during the procedure. This complication is very rare and has occurred in specific clinical settings: in patients with an extremely severe form of pectus excavatum, and in patients who have developed pericardial adhesions following previous thoracic or cardiac surgery. We consider that these patients should be operated with a cardiac surgery team ready to address any intra- or postoperative complication. In such cases, we do not use thoracoscopy, but rather a subxiphoid open approach and blunt dissection of the retrosternal area.

The classic Nuss technique is in our opinion the gold standard for children with a moderate symmetrical pectus excavatum deformity. Other procedures should however be considered to avoid complications, in other types of deformities.

Copyright © 2010 Elsevier Masson SAS. All rights reserved.

Traitement du thorax en entonnoir de l'enfant par voie mini-invasive

Jouve JL¹

¹Service de chirurgie orthopédique et pédiatrique, hôpital Timone enfants, Marseille. Service de chirurgie orthopédique et pédiatrique, hôpital Timone enfants, 13385 Marseille cedex 5. Email : Jean-luc.jouve@ap-hm.fr

e-mémoires de l'Académie Nationale de Chirurgie 2010 ;9(1):09-11

Résumé

Le *pectus excavatum* (PE) est la malformation congénitale thoracique la plus fréquente affectant une naissance sur 400, à prédominance masculine. Les étiologies sont multiples, idiopathiques (50 % des cas), héréditaires (40 % des cas) ou entrent dans le cadre des collagénoses telles que la maladie de Marfan. Dans la très grande majorité des cas, la déformation n'entraîne qu'un problème esthétique. Aucun retentissement cardiorespiratoire n'est à craindre. Cependant, certains adolescents présentent un état de souffrance psychologique important au point de refuser de mettre un maillot de bain ou de porter des vêtements légers. Les formes sévères avec retentissement cardiorespiratoire sont rares, le plus souvent associées à une maladie de Marfan ; les modifications de la structure ostéocartilagineuse peuvent être la source de compressions du contenu intra-thoracique. Jusqu'à une période récente, deux types de traitement existaient : par complément de l'excavation ou au moyen d'ostéotomies étagées à ciel ouvert. Les techniques de correction par voie endoscopique mini-invasive sont réservées aux formes symétriques médianes qui sont les plus fréquentes. Le principe repose sur la mise en place d'une plaque rétrosternale qui soulève le sternum vers l'avant en prenant appui sur les grills costaux droit et gauche. Ce geste est possible grâce à l'élasticité très importante qui permet des corrections sans qu'il soit nécessaire de réaliser de section cartilagineuse ou costale. La plaque est introduite grâce à deux incisions latérales de quelques cm. Le passage de la plaque se fait sous contrôle thoracoscopique et avec des guides dont la courbure est adaptée à la déformation. La plaque, préalablement cintrée à la forme désirée est passée d'une incision à l'autre, concavité dirigée vers l'avant pour ne pas risquer de lésion viscérale. Une rotation de 180° est ensuite effectuée permettant une correction instantanée. La reprise de la scolarité se fait à la 3e semaine. La reprise sportive sans restriction se fait au 2e mois. Il est recommandé de conserver la plaque entre 2 et 3 ans. L'ablation de la plaque est un geste simple qui justifie une hospitalisation de 24 h et n'impose pas de nouvelle thoroscopie. L'âge idéal de l'intervention est entre 7 et 18 ans. La diminution d'élasticité du thorax chez l'adulte diminue la qualité des résultats et des suites opératoires. Dans les formes sévères comme certains cas de maladie de Marfan, nous avons décrit une variante consistant à soulever le sternum par une courte incision sous l'apophyse xiphôïde. Ceci permet un passage de plaque en toute sécurité. Nous avons actuellement opéré plus de 50 enfants par cette technique. L'âge moyen allait de 5 à 18 ans. Nous n'avons pas déploré de complication majeure. Deux patients ont bénéficié d'un drain thoracique secondaire au 2e jour. Il n'y a pas eu de problème cardiorespiratoire. À ce jour, près de la moitié des patients ont vu leur plaque retirée avec des résultats stables et un indice de satisfaction élevé.

Copyright © 2009 Académie nationale de chirurgie. All rights reserved.

MEDICALEX

Correction chirurgicale mini-invasive du pectus excavatum de l'enfant et de l'adolescent : résultats d'une étude bicentrique à propos de 100 cas

Burnier M¹, Jouve JL, Kohler R, Kabbaj R, Dubois R

¹50, cours de la Liberté, 69003 Lyon, France

Revue de Chirurgie Orthopédique et Traumatologique 2013;99(7S):S322. doi: 10.1016/j.rcot.2013.09.131

RESUME/INTRODUCTION : Le pectus excavatum (PE) est une malformation congénitale fréquente. La technique mini-invasive de Nuss consiste à un relever le sternum par une plaque introduite sous contrôle thoracoscopique. Nous présentons une série de 100 enfants qui ont bénéficié d'une correction chirurgicale selon cette technique.

PATIENTS ET METHODE : Il s'agit d'une étude rétrospective et bicentrique. Notre série comporte 100 patients dont 77 hommes et 23 femmes. La moyenne d'âge est de 13ans. L'indication opératoire était cosmétique dans 93 % des cas. Trois paramètres scannographiques ont été mesurés en préopératoire. Quarante-vingt-dix patients ont été opérés selon la technique de Nuss originale. Dix patients ont nécessité une voie d'abord complémentaire sous-xiphoidienne sans contrôle endoscopique. Tous les patients ont bénéficié d'une radiographie du thorax en postopératoire immédiat. L'analgésie postopératoire a été réalisée par des antalgiques de 3^e pallier. L'ablation de la plaque a été réalisée entre 2 et 3ans après la pose.

RESULTATS : En peropératoire, nous avons retrouvé une contusion péricardique sans gravité et un trouble du rythme cardiaque. Les suites postopératoires ont été simples dans 84 % des cas, 15 complications mineures et 1 majeure ont été relevées. À 1 mois, 18 complications précoces (17 mineures et 1 majeure) ont été notées. Parmi les complications tardives, nous avons retrouvé 9 mineures et 3 majeures. Le résultat cosmétique a été jugé satisfaisant chez tous les patients.

DISCUSSION : La faible rançon cicatricielle et la fiabilité du résultat obtenu sont en faveur de la diffusion de la technique de Nuss. L'aspect inesthétique avec un retentissement psychologique représente sa principale indication. Les formes très sévères justifient pour nous une voie d'abord sous-xiphoidienne complémentaire. Le drainage thoracique n'est plus systématique dans les formes simples. Nos taux de complications étaient similaires aux données de la littérature (43 % mineures, 3 % majeures).

CONCLUSION : L'utilisation de la technique mini-invasive de Nuss dans la prise en charge des pectus excavatum tend à se généraliser pour des indications esthétiques dans les formes symétriques. La place d'une voie sous-xiphoidienne est recommandée dans les formes très sévères et/ou à forte rotation sternale.

Copyright © 2013 Elsevier Masson SAS. All rights reserved.

Analyse rétrospective des complications des thoracoplasties selon la technique de Nuss pour Pectus Excavatum. Série monocentrique de 76 patients. Revue de la littérature

Journé A¹, Wicart P, Revillon Y, Glorion C

¹13, avenue Boudon, 75016 Paris, France

Revue de Chirurgie Orthopédique et Traumatologique 2013;99(7S):S318. doi: 10.1016/j.rcot.2013.09.121

INTRODUCTION : La thoracoplastie selon la technique de Nuss est une intervention à visée esthétique qui permet de corriger un thorax en entonnoir de façon extemporanée. C'est une technique mini-invasive dont les complications sont fréquentes et qui peuvent mettre en jeu le pronostic vital. L'objectif de notre étude est d'analyser les complications postopératoires de cette technique afin d'en diminuer leur survenue.

PATIENTS ET METHODE : Il s'agit d'une série monocentrique de 76 patients composée de 20 filles et 56 garçons. L'âge moyen lors de l'intervention était de 14ans (7-18ans). Tous les patients ont été opérés selon la technique de Nuss avec mise en place de 1 barre dans 74 cas et de 2 barres dans 2 cas. Trois patients étaient atteints d'une maladie de Marfan, 9 patients avaient une cyphose thoracique et 3 une scoliose.

RESULTATS : La durée moyenne d'intervention était de 89minutes (45-180min). L'ablation du matériel a été faite chez 36 patients (47 %) à un délai moyen de 32 mois (8-36mois). Le taux de complications postopératoires était de 23 %. Les hémithorax étaient la complication la plus fréquente avec 7 cas (9,2 %) et nous avons dénombré 5 pneumothorax (6,6 %) dont un bilatéral. Nous avons observé 5 cas de déplacement de la barre (6,6 %) et une infection postopératoire (1,3 %). Trois patients (3,9 %) ont présenté une perte de correction après ablation de la barre.

DISCUSSION : Si la perforation cardiaque est la complication la plus grave de l'intervention de Nuss, elle reste exceptionnelle, le déplacement de la barre avec perte de correction est la complication la plus fréquente avec un taux allant de 4 à 14 %. Les méthodes permettant d'éviter les déplacements ne font pas consensus et vont de la mise en place de deux barres systématiques à la fixation par 5 points d'ancrage. Les hémithorax surviennent dans 1 à 17 % des cas et nous rapportons un taux de 9,2 %. Les pneumothorax varient de 2 à 12 %. Les infections sont rares et nous ne rapportons qu'un seul cas. Les pertes de correction après l'ablation du matériel sont peu fréquentes et sont généralement minimales.

CONCLUSION : La thoracoplastie selon la technique de Nuss est une intervention à visée esthétique dont les résultats sont immédiats et spectaculaires. Cette intervention mini-invasive a toutefois des complications fréquentes qui peuvent mettre en jeu le pronostic vital et ne doit être envisagée que dans les centres spécialisés bénéficiant de chirurgiens thoraciques, orthopédique et de soins de réanimation.

Copyright © 2013 Elsevier Masson SAS. All rights reserved.

Pectus excavatum : contre-indications à la technique de Nuss chez l'enfant et alternative thérapeutique

Kabbaj R¹, Viehweger E, Choufani E, Launay F, Afonso D, Jouve JL

¹Service de chirurgie orthopédique et pédiatrique, hôpital Timone-Enfants, 264, rue Saint-Pierre, 13005 Marseille, France

Revue de Chirurgie Orthopédique et Traumatologique 2012;98(7S):S327. doi : 10.1016/j.rcot.2012.08.134

La technique de Nuss est désormais couramment indiquée chez l'enfant. La forme symétrique peu sévère en constitue la meilleure indication. Cependant, certaines complications décrites dans la littérature en démontrent les limites. A partir d'une série de 80 cas nous présentons nos contre-indications à cette technique et une alternative thérapeutique chirurgicale.

PATIENTS ET METHODES : Quarante-deux patients ont été opérés d'un pectus excavatum entre 2004 et 2011 par le même opérateur. Soixante et onze d'entre eux ont bénéficié de la mise en place classique d'une ou de deux plaques rétrosternales sous contrôle thoracoscopique. Pour les neuf autres patients, il a été pratiqué une troisième incision médiane en regard de l'appendice xiphoïde permettant de contrôler au doigt le passage de la plaque sans thoracoscopie. Ce deuxième groupe était constitué de huit garçons et une fille avec une moyenne d'âge de 14ans. Ils avaient tous bénéficié d'un scanner thoracique préopératoire permettant de juger de la sévérité de la déformation suivant l'index de Haller, la distance sternum-corps vertébral et l'angle de rotation sternale. Tous les patients ont bénéficié d'un suivi clinique régulier.

RESULTATS : Tous les patients opérés selon la procédure de Nuss présentaient des déformations thoraciques symétriques. Il n'y a pas eu de complication sévère à noter. Dans le second groupe opéré avec un abord sous-xiphoïdien, deux enfants avaient été opérés d'une cardiopathie congénitale, deux enfants avaient des antécédents de chirurgie pulmonaire. Un patient présentait une récurrence de sa déformation après échec de la chirurgie classique et quatre enfants étaient porteurs d'une déformation asymétrique ou très sévère. Nous n'avons pas noté de complications per et postopératoire. La durée moyenne d'hospitalisation était identique dans les deux groupes. Le résultat cosmétique était jugé satisfaisant dans les neuf cas opérés par voie sous et rétro xiphoïdienne.

DISCUSSION : La littérature retrouve des complications rares mais dramatiques lors de la technique de Nuss. Nous considérons cette méthode indiquée dans trois circonstances :

- Les antécédents de chirurgie cardiothoraciques générateurs d'adhérences pariétales dangereuses ;
- Les formes symétriques profondes avec une distance sternum-rachis inférieure à 30 mm ;
- Les formes asymétriques importantes avec un angle de rotation sternale supérieur à 30°. Ces formes donnent des résultats cosmétiques décevants et empêchent un bon contrôle endoscopique de l'espace rétrosternal.

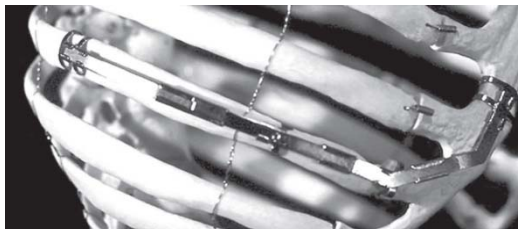L'indice de Haller n'a que peu d'influence sur les indications. Dans ces cas, un court abord sous-xiphoïdien permet de sécuriser le passage de la plaque thoracique.

Copyright © 2012 Elsevier Masson SAS. All rights reserved.

Indication

Traitement chirurgical des déformations de la paroi thoracique par sternochondroplastie
Stabilisation chirurgicale des fractures costales, volets thoraciques et thoracotomies
Reconstruction thoracique après résection tumorale

*Surgical treatment of chest wall deformities by sternochondroplasty
Surgical stabilization of costal fractures, flail chest and thoracotomies
Thoracic reconstruction after tumoral resection*



Bibliographie / Bibliography

9th PERFECTO workshop: Pr Borrelly's staple-struts – 5th of June 1997

MEDICALEX

Available online at www.medicalex.info

Surgery of thoracic malformations: the experience of Percy Army hospital 1988-2006

Jancovici R¹, Arigon JP², Pons F²

¹Hôpital Américain de Paris, Centre Chirurgical du Val d'Or - Saint Cloud, jancovici@gmail.com

²Hôpital Percy, Clamart

e-mémoires de l'Académie Nationale de Chirurgie 2007 ;6(4):09-19

Abstract

Since 1988, 113 patients have undergone repair of pectus chest deformities in our institution: there were 93 with pectus excavatum (PE) (82%), 18 with pectus carinatum (PC) (16%), and 2 with pectus arcuatum (PA) (2%). All patients underwent sternochondroplasty procedure with a variation of modified Ravitch repair technique. Ninety-two percent of patients considered the result after repair to be perfect. This procedure needs an anterior thoracic approach, with a sufficient mobilization of the skin and the pectoralis muscles up to the angle of Louis, and with the removing of abdominal muscles from lower costal cartilage and xiphoid. Chondrotomies on ribs and even sternotomies with partial resection of sternocostal cartilages were performed to obtain the correction of the deformity.

We obtain a real "puzzle" that needs to be stabilized with specific osteosynthesis material: The Martin and Borrelly's kit. These bars are placed under the sternum on his back face with PE and placed across on the anterior of the sternum with PC if necessary. With PA (PE+PC), the material is placed alternatively on the posterior and anterior part of the sternum. Since few years, the pectoralis muscles were reconstructed with an accentuated medialization to cover the middle line in association with costal and cartilaginous repair. All patients underwent a physical preparation with preoperative and postoperative muscular training. Some patients considered initially very longineal and sometimes like "frangible" individual became sportsman and real athletes.

In only 4 % of patients, we considered the persistence or recurrent minimal deformities from sternal concavity, generally in patients who didn't practice enough sport. All of them, had new repair using an accentuated medialization of pectoralis muscles, and sometimes we realized a "lipofeeeling". Also, 4 patients presented early rupture of the Martin and Borrelly's material, which was removed generally during few months after intervention. Indeed, broken material retained under posterior part of the sternum, remain certainly a danger for the heart.

Also, skin necrosis localized in front of the incision has occurred in 2 patients. They required a healing by granulation. We will remind that nowadays in France an American technique described by Doctor NUSS is also developed. This will be shortly described by our friend Gilles Grosdidier from NANCY. This procedure seems to be particularly adapted for young patients with PE.

Copyright © 2007 Académie nationale de chirurgie. All rights reserved.

Surgical correction of pectus excavatum deformity and hypomastia

Bodin F¹, Bruant-Rodier C¹, Wilk A¹, Wihlm JM²

¹Service de Chirurgie plastique et Reconstructrice Hôpital civil-1 place de l'hôpital-B.P. N° 426 67091 Strasbourg Cedex France

²Department of Thoracic Surgery Strasbourg University Hospital, Strasbourg, France

Eur J Plast Surg 2008;31(1):15-20. doi: 10.1007/s00238-007-0210-2

Abstract

Female patients occasionally present with major pectus excavatum and hypomastia. The aim of this study was to investigate the clinical outcome of female patients who had combined surgical correction of both deformities. Since 1990, 12 young female patients underwent correction using a modelling sternochondroplasty with osteosynthesis using Borrelly's slide fastener-handle. After 1 year, the material was removed, and the breast implants were placed in the subpectoral plane. Our investigation was based on functional, morphological, aesthetic and psychological criteria. Despite nonsignificant pulmonary function tests ($p < 0.05$), we noted a subjective improvement of physical capacity during exercise following pectus excavatum repair. Correction of thorax deformity increased the sternovertebral distance by a mean of 3.2 cm (range 1.5–5.5 cm) thus treating mediastinal compression. As for aesthetic results, all patients were satisfied or very satisfied. The psychological benefit was considered as phenomenal after surgical treatment. Repair of pectus excavatum by sternochondroplasty combined with correction of hypomastia for female patients suffering from a double deformity is possible with only two different operations.

Copyright © 2007 Springer-Verlag. All rights reserved.

[Our 5-year experience with the use of a new material for thoracic osteosynthesis: the sliding staple-splint].

[Article in French]

Borrelly J¹, Grosdidier G, Wack B

¹Service de Chirurgie E, Hôpital Central, 29, avenue du Maréchal-de-Lattre-de-Tassigny, 54000 Nancy

Ann Chir. : Chir thorac cardio-vasc 1985 Oct;39(7):465-70.

Abstract

The authors report their experience with a new chest osteosynthesis device, the slide staple splint (SSS). Out of a total of 388 chest traumas treated over a 12-years period, 79 required osteosynthesis. Of these, the last 43 benefited from the new device, whose main advantage resides in the stability of the osteosynthesis, and therefore in a reduction of the average duration of artificial ventilation. The mean duration of artificial ventilation was reduced from 5.8 days (less than 24 hours in 50 per cent of cases) for the first 36 patients treated with the SSS, to 2.6 days (under 24 hours for 80 per cent of cases) for the last 43. Artificial ventilation is therefore only used now when it is necessary – i.e. in the one third of the patients presenting with parietal instability. Moreover, this device allows a far bolder approach to deformations of the chest wall, and to the extent to which the chest wall can be resected in carcinology.

PMID: 4083759 [PubMed - indexed for MEDLINE]

Repair of the anterior chest wall malformations: modelling osteochondroplasty and stabilization by Borrelly sliding splint stapler

Nloja J¹, Grosdidier G

¹Service de chirurgie générale et thoracique du professeur Gilles Grosdidier, CHU - hôpital central, 29, avenue du Maréchal-de-Lattre-de-Tassigny, 54035 Nancy cedex, France

EMC-Chirurgie 2 2005;100-106. doi: 10.1016/S1241-8226(05)39121-3

Abstract

Congenital malformations of the anterior chest wall rarely induce organic clinical symptomatology. The principal indication for surgery is the psychological impact for the young adult. The modelling technique referred as osteochondroplasty with stabilization by sliding splint staplers can be selected in the three following types of deformations: *pectus excavatum*, *pectus carinatum* and *pectus arcuatum*. Such procedure requires good anatomical knowledge of the thoracic malformation because it induces major modifications of the chest resulting from various osteotomies and chondrotomies. These latter interventions are aimed at constructing a real sternochondrocostal shutter which is stabilized afterwards by osteosynthesis using Borrelly's splint staplers; these staples are positioned, after correction, behind or in front of the breastbone depending on the type of malformation. This technique that requires multidisciplinary management (anaesthetists, thoracic surgeons, plastics surgeons and kinesiotherapists) allows obtaining good morphological results, by restitution of normal anatomic properties to the anterior chest wall.

Copyright © 2013 Elsevier Masson SAS. All rights reserved.

[Wide resection of a pulsatile metastatic tumor of the manubrium sterni. Reconstruction by sliding clip splints].

[Article in French]

Borrelly J¹, Grosdidier G, Maestracci C

¹Service de Chirurgie E, Hôpital Central, 29, avenue du Maréchal-de-Lattre-de-Tassigny, 54000 Nancy

Ann Chir. : Chir thorac cardio-vasc 1987;41(6):498-502.

Abstract

The authors present the case of a 60 years old woman who underwent two thyroid operations in 1973 and then in 1980 (façade bilobectomy in 1973, total right lobectomy in 1980). A hypervascularised pulsatile tumor of the manubrium sterni was resected en bloc with the two median extremities of the clavicles and the two pairs of the first costal cartilages on January 22 1985. This was a highly differentiated thyroid metastasis. Reconstruction was achieved by the use of two sliding clip splints, one placed between the two second ribs and the other placed between the two clavicles. The functional result in terms of movement of the two shoulder girdles was excellent and the carcinological result is currently stable.

PMID: 4083759 [PubMed - indexed for MEDLINE]

Complete chest wall reconstruction after en bloc excisions with Gore-Tex®/Marlex®/ Flap sandwich. A retrospective study of 14 cases

Danino A¹, Saito S¹, Cuminet J¹, Debrosse D², Gossot D², Le Pinsec-Barthes F³, Revol M¹, Riquet M³, Servant JM¹

¹ Service de chirurgie plastique (Pr J.M. Servant), hôpital Saint-Louis, 1, avenue Claude-Vellefaux, 75010 Paris, France

² Service de chirurgie thoracique, institut mutualiste Montsouris, 42, boulevard Jourdan, 75014 Paris, France

³ Service de chirurgie thoracique, hôpital européen Georges-Pompidou, 20, rue Leblanc, 75908 Paris cedex 15, France

Annales de chirurgie plastique esthétique 2003 Apr;48(2):86-92. doi: 10.1016/S0294-1260(03)00011-6

Abstract

To assess the results of surgical resection and chest wall reconstruction we reviewed our experience with the complete chest wall reconstruction after en bloc excisions according to an original algorithm based on the location of the thoracic defect. The 14 reconstructions were performed by the senior author. We found 5 central, 6 lateral and 3 borders locations. In the central locations with a total resection of the sternum the reconstruction was realized by Gore-tex's® mesh in depth, metal hooks (staples) and Marlex's® mesh under a musculocutaneous flap of coverage. In case of lateral location the reconstruction was realized by Gore-tex's® mesh covered with a musculocutaneous flap, the borders locations were reconstructed by Marlex's mesh and flap of coverage. The histological diagnoses were: one desmoid tumor, eight sarcomas, a recurrence of hepatocarcinoma and four recurrences of breast cancer. The superficial coverage performed by latissimus dorsi flap 12 for cases and rectus abdominis flap for two cases. All the patients were able to produce a spontaneous breath after surgery. Two deaths at distance and an infection were to regret. On the whole the algorithm of reconstruction according to the location of the defect allows a simplification of the indications.

Copyright © 2003 Éditions scientifiques et médicales Elsevier SAS. All rights reserved.

[Current role of osteosynthesis in the treatment of severe chest injuries with parietal instability].

[Article in French]

Borrelly J¹, Grosdidier G, Wack B, Boileau S, Skorintschouk I

¹Service de Chirurgie E, Hôpital Central, 29, avenue du Maréchal-de-Lattre-de-Tassigny, 54000 Nancy

Chirurgie 1987;113(5):419-26.

Abstract

Severe thoracic trauma must not be abandoned to anaesthetists although the improvement in new technics of mechanical ventilation and analgesia methods. Our conclusion from our last series of 36 thoracic trauma with flail chest treated in 1985 and 1986 is that osteosynthesis keeps an important place if the material used (sliding-staples) is malleable and well tightened. This series (III) is compared with a first series (I) of 139 flail chest (1972-1979) and a second series (II) of 98 flail chest (1980-1984).

Therapeutic indications depend on many factors and may change while evolution.

We consider that prolonged mechanical ventilation (internal pneumatic stabilization) is indicated in patients with severe neurological injury, pulmonary contusion, polyvisceral distress or when other methods have been uneffective. This procedure has been used in 62% (I), 43% (II) and 42% (III) and allowed shorter duration of mechanical ventilation among the survivors from 10.3 days (I) to 7.3 days (II) and then to 2.18 days (III).

In the last period, conservative means as analgesia technics and continuous positive airway pressure (CPAP) have been more effective 35% (I), 62% (II) and 69% (III), so they were required as the only treatment in respectively 16% (I), 23% (II) and 31% (III).

Osteosynthesis, considered as a reasonable bet to overcome prolonged mechanical ventilation or reduce its duration, has been required in respectively 30% (I), 39% (II) and 42% (III) in each series, with an effectiveness of 53% (I), 82% (II) and 60% (III).

Different treatment modalities must not be opposed and results must only be analyzed considering all factors.

PMID: 3691226 [PubMed - indexed for MEDLINE]

MEDICALEX

20 avenue Aristide Briand 92220 BAGNEUX – France www.medicallex.info
Tél : +33 (0)1 46 11 16 20 Fax : +33 (0)1 46 65 41 41 francemed@wanadoo.fr

New insights into the pathophysiology of flail segment: the implications of anterior serratus muscle in parietal failure.

Borrelly J¹, Aazami MH.

¹Medipole Gentilly-Saint Jacques, 54320 Maxeville, France.

Eur J Cardiothorac Surg. 2005 Nov;28(5):742-9. Epub 2005 Oct 7. doi: 10.1016/j.ejcts.2005.08.017

Abstract

OBJECTIVE: The wisdom of surgery facing multiple and multi-focal ribs fractures (flail segment) remains controversial. By the present retrospective study, we sought to determine the advisability of surgery as well as the anatomical and biomechanical features of flail segment leading to secondary dislocation.

METHOD: From 1970 to 2000, 127 patients underwent flail segment osteosynthesis. Clinical charts, operative reports and imaging data were reviewed retrospectively. Rib osteosynthesis was carried out with Judet staple and Kirschner wires until 1980, since then it has been undertaken with sliding-staples-struts. Postoperative chest X-ray was carried out to classify the flail segments into anterolateral and posterolateral types according to the location of anterior and posterior rib fractures. Each type was then divided into three subgroups of primary parietal, secondary parietal and retreat indications that were inferred retrospectively from final indications of rib osteosynthesis.

RESULTS: The mean age of patients (ranging in age from 20 to 84 years) was 56+/-14.4 years with a male predominance (108/19). Seventy percent of flail segments was considered as posterolateral. The mean number of rib fractures per patient was 6+/-0.35. Rib osteosynthesis was undertaken with sliding-staples-struts in 70% of patients. The overall hospital mortality was 16%; it was subsequently reduced to 8% since sliding-staples-struts were used. The mean duration of ventilation was reduced from 5.8+/-0.76 days to 2.98+/-0.83 days with sliding-staples-struts. Seventy-seven percent of patients with posterolateral flail segment and primary parietal indication were extubated within the first 48 h postoperatively, whereas 46% of patients from other subgroups required ventilation for more than 5 days. Similarly, 83% of patients of the former subgroup returned to full previous level of activity compared with a rate of 52% for the latter subgroups. The flail segments were dislocated superoposteriorly for both anterolateral and posterolateral types, evoking the action of anterior serratus muscle.

CONCLUSIONS: The anterolateral and posterolateral flail segments are rendered susceptible to secondary dislocation through a complex set of factors, of which the action of anterior serratus muscle is obvious. Restoration of parietal mechanics by early surgical reduction/fixation is a reliable therapeutic option in selected patients and offers encouraging results.

PMID: 16214360 [PubMed - indexed for MEDLINE]

Chapter 101 – Chest wall trauma: The traumatic failing chest wall

Borrelly J, Aazami MH.

In the Second volume of the ESTS Textbook of Thoracic Surgery, Forthcoming

Subchapter 6 – Chest wall stabilization: surgical restoration of the traumatic failing chest wall

Borrelly J, Aazami MH.

In Chapter 106 – Trauma: operative techniques of the Second volume of the ESTS Textbook of Thoracic Surgery, Forthcoming